

i-CAT Cone Beam Volumetric Tomography Scan

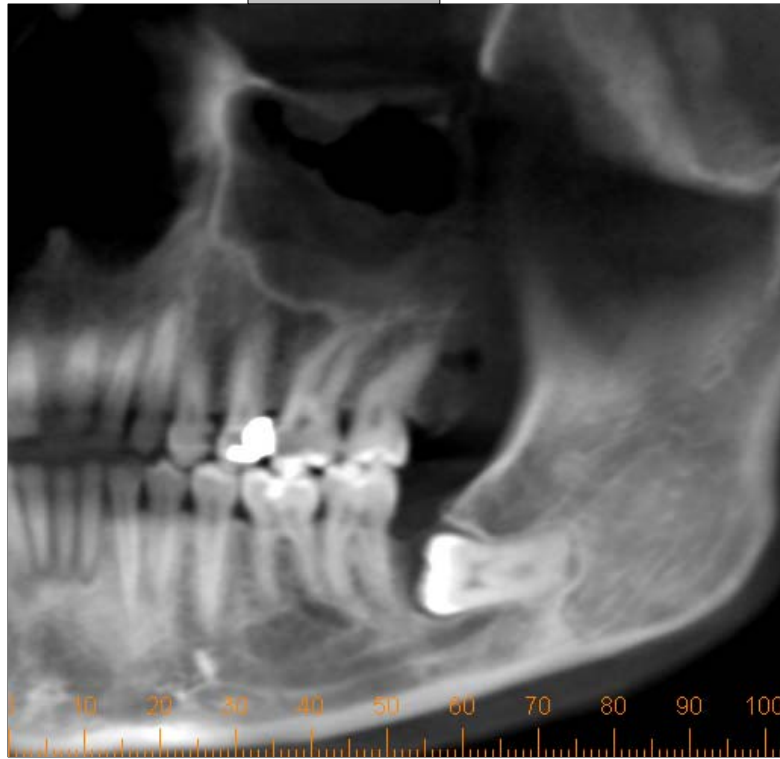
Golden State X-Ray
5451 Laurel Canyon Blvd. Ste. #202
North Hollywood, CA 91607
Tel: (818) 506-6861

Patient: Third Molar
DOB: 11/22/1964
Referred by:
Study Date: 04/08/2004 10:50:22

Right

7.6 mm sagittal

Left



All views are actual size (1:1)

