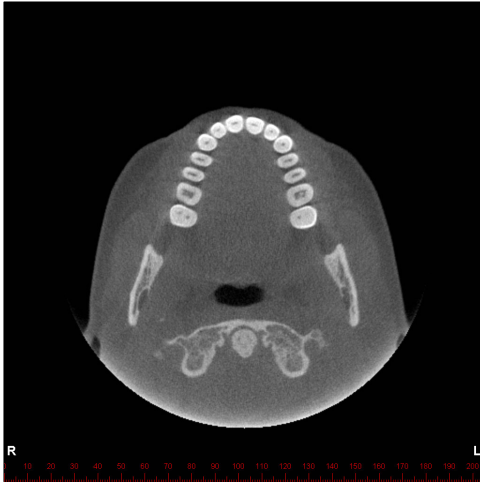

i-CAT Custom Report

Imaging Sciences International, Inc.
1910 North Penn Rd.
Hatfield, PA 19440
800-205-3570

Patient: MaxMand Sample
DOB: 1/1/2001
Referred by:
Study Date: 08/06/2003 17:40:17

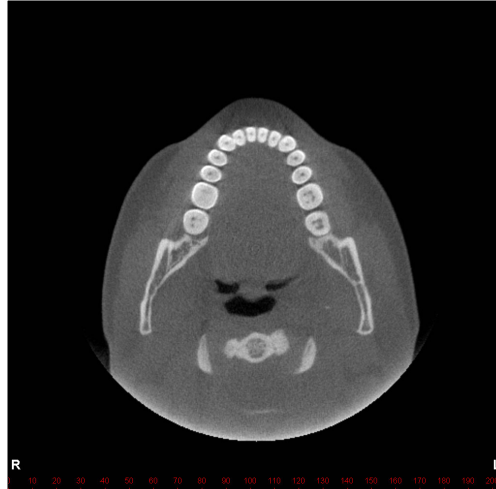Maxillary Crowns



RIGHT

LEFT

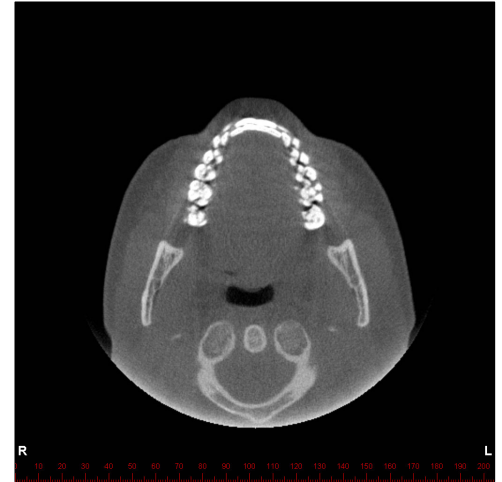
Mandibular Crowns



RIGHT

LEFT

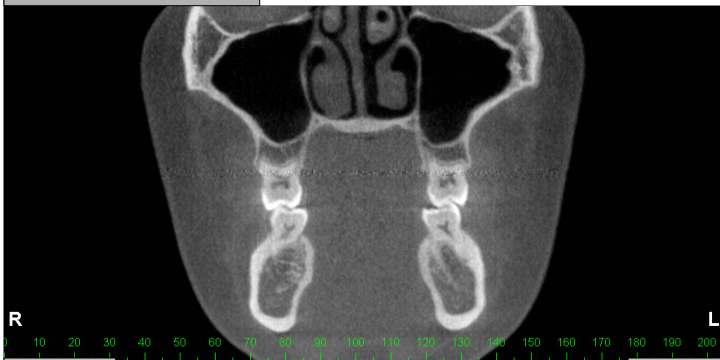Occlusion



RIGHT

LEFT

Coronal
First Molar Region



RIGHT

LEFT

Midsagittal Slice

